

Canine Hip Dysplasia

Canine hip dysplasia is characterized by varying degrees of hip joint laxity (looseness), subluxation (partial dislocation), and ultimately, severe arthritic change. Clinically, the symptoms range from having no clinical signs in some affected dogs to crippling disease in others. In addition, the severity of the clinical signs does not necessarily correlate with the degree of radiographic (x-ray) or pathologic changes seen. Breed and individual differences in temperament may also affect the amount of discomfort exhibited.

Development

Hip dysplasia is a genetically transmitted disease that has been seen in over 82 recognized breeds of dogs. Since first diagnosed in 1935, it has had the highest incidence in the larger breed animals.

Hip dysplasia is an inherited, developmental disease with a polygenic mode of inheritance. This means that there are multiple genes which must be present for this disease to express itself. Surprisingly, the hip joints of dogs which develop dysplasia are normal at birth. In most cases, dysplasia will occur in both legs (bilaterally). However, in approximately 7% of the cases only one hip will be affected.

One of the earliest programs to reduce hip dysplasia was begun in 1959 by the Swedish Kennel Club. They required that a certificate of normal hips (diagnosed by radiographs) be provided for any German Shepherd to be awarded a championship, to compete in a best of sire class, to be given a special prize for working dogs, or if imported, to be registered in Sweden. Breeders were thus encouraged to breed only dogs found to be free of hip dysplasia.

Unfortunately, the incidence of hip dysplasia in Swedish German Shepherds did not decline as rapidly as had been hoped when the scheme was put into operation. In fact, ten years of selective breeding failed to reduce the number of moderate and severe cases. The common belief that if no dysplastic dogs became parents the defect would then disappear was simply not true. Two radiographically sound dogs may still produce dysplastic offspring if the genes responsible for this disease are present.

In one study, a 37.5% incidence of dysplastic puppies from normal parents was observed. This indicates that the genes tending to induce hip dysplasia are widespread in certain breeds and that radiographs showing normal hips, although highly desirable, are no guarantee of normal hips in offspring. Similarly, parents that are superior with respect to any character are more likely to produce superior progeny than are parents less fortunate but they can not be counted on to do so.

Several secondary factors also influence the development of dysplasia. These include body size, body conformation, and growth patterns. When the genetic potential for dysplasia is present, feeding a high calorie, high protein diet which produces rapid weight gain will increase the incidence and severity of the disease.

The degree of hind leg muscle mass is also related to the prevalence of dysplasia. In German Shepherd dogs, the greater the amount of musculature of the rear limbs, the lower the incidence of dysplasia. Well balanced muscular support is necessary to maintain proper joint alignment. Weakness of the hip muscles can lead to adverse changes in developing hip joints.

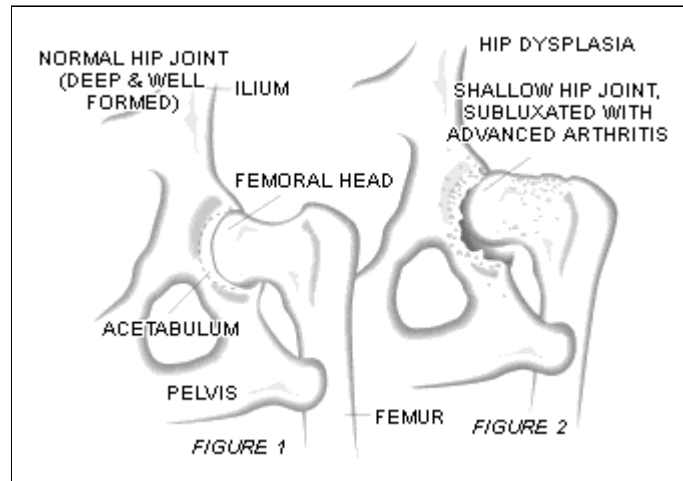
If the muscles of the hindlimbs fail to develop and reach functional maturity at the same rate as the bones of the hindlimbs, the result is an incongruency between muscular support and skeletal growth which may lead to joint instability. This eventually will progress to degenerative arthritis. This theory is supported by the fact that Greyhounds, with tremendous muscular support for a fine, bony skeleton, rarely have hip dysplasia.

Clinical Signs

The primary abnormality in canine hip dysplasia is joint laxity. This may lead to inflammation within

the joint and result in pain and lameness. This joint laxity in young dogs initiates a vicious cycle, wherein movement and weightbearing force the femoral head (the ball portion of the hip joint) into an abnormal position. This causes interference with the ossification (formation of bone) of the acetabular rim (hip socket), erosion and fibrillation of the joint cartilage, stretching of the round ligament, inflammatory changes in the synovial membrane (joint lining), thickening of the joint capsule, and formation of osteophytes (bone spurs).

The result is an abnormally shallow acetabulum and a flattened femoral head. Ultimately, the joint undergoes degeneration through this arthritic process (Fig. 1 & 2).



The acute and prolonged pain and crippled movement in young dogs is the result of the sudden occurrence of microfractures (small cracks or fissures) on the acetabular rim. These fractures are not visible radiographically because they are hidden behind the femoral head. They occur as a result of prolonged fatigue and bending of the immature bone of the acetabular rim while weightbearing and in motion. The changes seen in a young dog's gait may include reluctance to jump, a "bunny hop" gait when running, and limping. Some dogs may cry out in pain upon movement of the hip.

Each pelvic (hip) radiograph submitted to the OFA is evaluated by three diplomates of the American College of Veterinary Radiologists. By consensus, the hip joint conformation is classified as excellent, good, fair, borderline, mildly dysplastic, or severely dysplastic. Classification as excellent, good, or fair is considered within normal limits. If the dog is two years of age or older, a breed registry number is assigned and the dog is then certified. Dogs must be two years of age to be certified because it has been established that 94% of all dysplastic dogs will show radiographic evidence of their disease by two years of age.

The ultimate purpose of OFA certification is to provide information to dog owners to assist them with the selection of good breeding animals. Therefore, attempts to get a dysplastic dog certified will only hurt the breed by perpetuation of the disease.

Treatment

Treatment of hip dysplasia can be conservative or surgical. The objectives of conservative therapy are to relieve pain and maintain limb function, as well as to continue the dog in as normal a level of activity as possible. Conservative therapy consists of weight control, moderate exercise, and analgesics (pain relief medication). The most important element will always be the maintenance of muscular support. Muscle is built by walking, jogging, and swimming. Acrobatics (playing frisbee, jumping, etc.) should be avoided as they place unnecessary pressure on the joint.

Another medical approach to the treatment of degenerative arthritis secondary to hip dysplasia involves the use of products called polysulfated glycosaminoglycans or PSGAGs. PSGAGs are naturally occurring components of the joint cartilage and increase joint fluid production.

When should a patient receive conservative management as opposed to specific surgical treatment?

The answer depends on the age of the dog, the intended use of the dog, the degree of arthritis, the severity of the lameness, and the financial capability of the owner. Approximately 50-60% of the patients may respond to conservative therapy over a long period of time. The remaining 40-50% will require surgical treatment. Unfortunately, there is no way to predict into which category a dog will fall.

Three surgical procedures are currently used in the treatment of hip dysplasia. In young patients with minimal evidence of arthritis, a stabilizing reconstruction of the hip joint is recommended. This involves reconstructing the joint congruency and stopping the subluxation and laxity that lead to severe arthritis. This technique is called a triple pelvic osteotomy. It has been established as a reliable mode of treatment in cases which meet the case selection criteria.

Once the patient (usually adult) has radiographic evidence of degenerative arthritis, it is no longer a candidate for a triple pelvic osteotomy. Over time, many of these dogs will become less responsive to analgesic medications and surgical therapy should be considered. There are two procedures available.

- 1) Removal of the femoral head and neck (excision arthroplasty, femoral head ostectomy, FHO).
- 2) Total hip replacement.

Femoral head excision works well for dogs under thirty pounds and those with unilateral dysplasia. It is less satisfactory for dogs over fifty pounds, particularly when performed bilaterally. This is a salvage procedure for those owners who cannot afford the cost of a total hip replacement but need an alternative to constant medication and debilitating pain.

Introduced in 1976, the total hip replacement has become the only treatment available that provides normal hip joint function once advanced arthritis is present. With this technique, the femoral head and neck are replaced with a cobalt chrome or titanium component and the acetabulum is replaced with a plastic cup prosthesis. A five year followup study of 221 total hip replacements revealed an overall success rate of 91%. Total hip replacement can be done on both hips although many dogs (80-90%) do very well with one side replaced.